

Personal pdf file for

K. Konieczka, M. G. Todorova, T. N. Chackathayil, P. B. Henrich

With compliments of Georg Thieme Verlag

www.thieme.de

Cilioretinal Artery Occlusion in a Young Patient with Flammer Syndrome and Increased Retinal Venous Pressure

DOI 10.1055/s-0035-1545774

Klin Monatsbl Augenheilkd 2015; 232: 576–578

This electronic reprint is provided for non-commercial and personal use only: this reprint may be forwarded to individual colleagues or may be used on the author's homepage. This reprint is not provided for distribution in repositories, including social and scientific networks and platforms."

Publisher and Copyright:

© 2015 by
Georg Thieme Verlag KG
Rüdigerstraße 14
70469 Stuttgart
ISSN 0023-2165

Reprint with the
permission by
the publisher only

 **Thieme**

Cilioretinal Artery Occlusion in a Young Patient with Flammer Syndrome and Increased Retinal Venous Pressure

Verschluss einer zilioretinalen Arterie bei einem jungen Patienten mit Flammer-Syndrom und erhöhtem retinalen Venendruck

Background

Cilioretinal arteries stem from the posterior ciliary artery system and are found in roughly 32% of all eyes [1]. In 18.7% of the patients, a ciliary artery contributes to macular circulation [1]. In a large series of central artery occlusions, the conservation of some degree of macular function due to the existence of a cilioretinal artery could be observed in 26% of cases [2]. The opposite phenomenon, an occlusion of a cilioretinal artery (CLRAO), represents only 5% of all retinal arterial occlusions [3,4] but may be associated with a significant loss of central vision [3]. The median age of 49 years [3] is lower than that of other groups of retinal vascular occlusion. CLRAOs in very young patients under the age of 25 years are rare and have been described in conjunction with a wide array of general conditions, including cocaine use [5], increased intracranial pressure [6], Sturge-Weber-associated glaucoma [7], hypercoagulable states, and cardiac valvular diseases [4]. The concurrence of a CLRAO with a central retinal vein occlusion (CRVO) was first described in 1968 [8]. CLRAOs were assumed to be secondary to CRVO [9,10]. The proposed mechanism is a resulting reduction of the pressure gradient in the

cilioretinal artery [8,9]. We report a CLRAO in a young man with very high retinal venous pressure (RVP). Whereas this patient had neither classical vascular risk factors nor identifiable sources of emboli, he had signs of Flammer Syndrome [11–13]. The vasospastic syndrome (later called primary vascular dysregulation syndrome and today Flammer syndrome) has already been reported to predispose to both CRVO and CLRAO [14]. The increase of RVP, which in extreme cases leads to the clinical picture of a CRVO, has been described as a consequence of a local dysregulation of the central retinal vein [15]. Here we describe a case with CLRAO in the presence of very high RVP and we hypothesize that Flammer syndrome caused both a local constriction of the cilioretinal artery and of the central retinal vein. The latter increased RVP and thereby contributed to the pathogenesis of CLRAO.

Case Presentation

A 17-year-old male patient of European and Afro-American descent reported to the emergency room with a 2-day history of a central scotoma in his left eye. The scotoma had appeared abruptly while

watching television and had remained unchanged afterwards. Medical and family history were unremarkable except for one episode of atopic dermatitis 3 months previously and the presence of some signs and symptoms of a Flammer syndrome [11,12]. The patient, a high school student, was on no medication and denied smoking, alcohol or drug use. Visual acuity was 1.0 sc in the right eye and finger count at 50 cm sc in the left eye. Intraocular pressure was 13 mmHg and 16 mmHg, respectively. On ophthalmologic examination, the anterior segment was bilaterally unremarkable. Ocular fundus was within normal limits in the right eye but in the left eye showed a conspicuous, sharply demarcated, horizontally oval, whitish-greyish discoloration at the posterior pole, reaching from close to the optic disc margin to slightly temporally of the fovea. The fovea had a “cherry-red-spot” appearance (● Fig. 1). We suspected a CLRAO. No emboli could be identified. Ocular massage was performed, and the patient was admitted for further workup. His hematocrit was borderline at 0.52 but dropped to 0.44 following a single isovolemic hemodilution. Apart from an eosinophilia of $0.627 \times 10^9/l$ and a borderline monocytosis of $0.701 \times 10^9/l$, an extensive hematologic, thrombophilia and rheumatologic workup was negative, including the absence of sickle cells. Blood lipids and HbA1c were normal. Twenty-four-hour arterial blood pressure monitoring revealed the absence of a physiological nocturnal dipping. No indications for additional ischemic events or other abnormalities were found on cranial magnetic resonance imaging. Echocardiography, including transesophageal echocardiography, revealed no abnormalities. Neurovascular ultrasound examinations of the carotid and vertebral arteries were unremark-

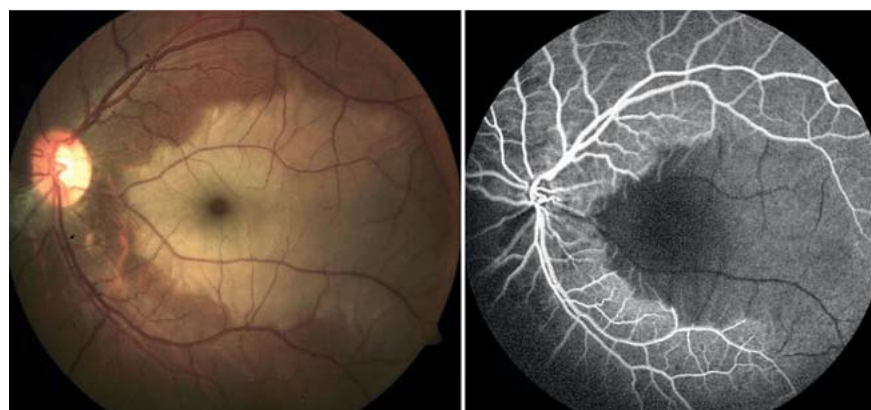


Fig. 1 Left: Fundus with white ischemic retina with a “cherry-red spot” appearance at the macula in an area supplied by a cilioretinal artery. Right: Corresponding fluorescein angiogram.

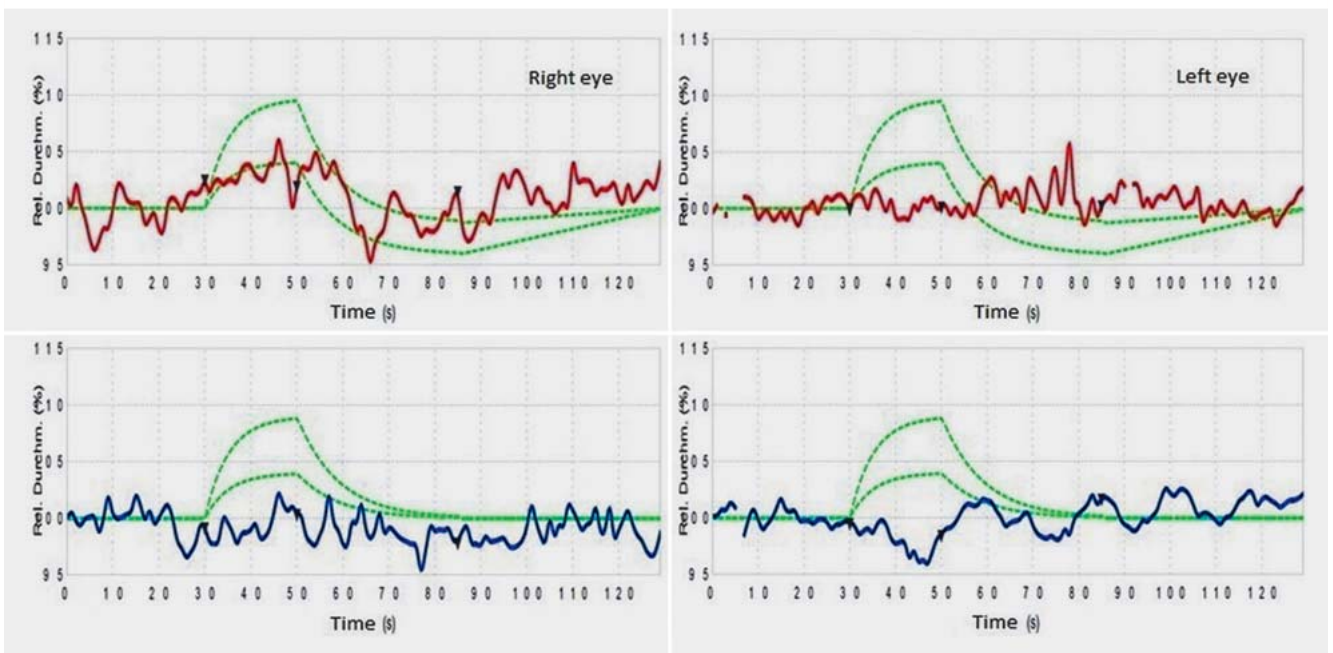


Fig. 2 Markedly reduced vasodilation to flickering light in arteries and veins of both the affected and non-affected eye, measured with a Dynamic Reti-

nal Vessel Analyzer (red, arteries; blue, veins; green, normal range of the responses).

Ophthalmological investigations

- ▶ Fluorescein angiography
- ▶ Optical coherence tomography (OCT)
- ▶ Goldmann perimetry
- ▶ Color Doppler imaging of the retroocular vessels
- ▶ Dynamic Retinal Vessel Analysis
- ▶ Ophthalmodynamometric measurement of retinal venous pressure

Systemic investigations

- ▶ Extensive hematologic investigations (such as full blood count, hemostasis investigations and thrombophilia screen)
- ▶ Erythrocyte sedimentation rate (ESR), C-Reactive Protein (CRP)
- ▶ Extensive rheumatologic investigations (rheumatoid factor, ANA, ANCA, etc.)
- ▶ Blood sugar and HbA1c
- ▶ Blood lipids
- ▶ Serum proteins
- ▶ 25-hydroxyvitamin D
- ▶ Twenty-four-hour arterial blood pressure monitoring
- ▶ Cardiovascular examinations, including transesophageal echocardiography
- ▶ Neurovascular examinations including ultrasonography of the carotid and vertebral arteries
- ▶ Cranial magnetic resonance imaging (MRI)

Table 1 List of investigations performed in this young patient with cilioretinal artery occlusion.

able. 25-hydroxyvitamin D was decreased to 14 nmol/l (normal values: 75–250 nmol/l), revealing an overt vitamin D deficiency.

RVP was markedly increased in the affected eye (75 mmHg) but also to some extent in the nonaffected eye (45 mmHg). Measurements with a Dynamic Retinal Vessel Analyzer (Imedos Systems UG, Jena, Germany) showed markedly reduced responses of retinal arteries and veins to flickering light stimulation in both eyes (► Fig. 2) as an indication for reduced neurovascular coupling and dysfunction of the endothelial cells of the retinal ves-

sels. Color Doppler imaging showed slightly reduced baseline blood flow velocities in the retrobulbar vessels in both eyes. A summary of the investigations performed are listed in ► Table 1.

In addition to the standard therapy with ocular massage, isovolemic hemodilution, aspirin, and dalteparin, we initiated a systemic treatment with nimodipine 30 mg per day and 36 000 IE of cholecalciferole per day. The following day, RVP had decreased from 75 to 64 mmHg in the affected eye and from 45 to 38 mmHg in the nonaffected eye. In the follow-up examinations under this therapy, we ob-

served reduction of RVP to 26–35 mmHg in the affected eye and to 18–36 mmHg in the nonaffected eye as well as normalization of ocular blood flow (OBF) in both eyes in the color Doppler imaging. However, this treatment improved the visual function only marginally, and a central scotoma in the affected eye remained. In addition, the responses of retinal arteries and veins to flickering light measured with a Dynamic Retinal Vessel Analyzer in both eyes improved but remained pathological. Vitamin D supplementation increased its concentration in circulating blood to normal values.

Discussion

We described a CLRAO in a young patient. Whereas this patient had neither classical vascular risk factors, nor identifiable sources of emboli or inflammatory diseases (such as Behçet disease, systemic lupus erythematosus, antiphospholipid syndrome or giant cell arteritis), RVP was markedly increased and responded well to a therapy with a calcium channel blocker (CCB). These conditions are in agreement with the assumption that an underlying condition, namely Flammer syndrome, may have predisposed this patient to such an arterial occlusion. The vitamin D deficiency may have further contributed to the risk.

Flammer syndrome [11–13] (previously called primary vascular dysregulation syndrome) refers to a predisposition to react differently to a number of stimuli, such as coldness or physical or emotional stress. The most prominent sign is the dysregulation of vessels. However, the syndrome encompasses a number of additional vascular and nonvascular signs and symptoms [11,12]. The most common signs are cold extremities and low blood pressure. Subjects with Flammer syndrome often take longer to fall asleep. They also have a reduced feeling of thirst but normally drink enough, as they know they need to do so. These subjects are generally more sensitive. They have increased sensitivity to certain drugs, increased pain sensation, increased sense of smell, and increased sensitivity to high altitude. They often suffer from tinnitus. Under psychological stress, an increased heterogeneity of skin perfusion (reversible red and white skin blotches) is observed in some subjects. The syndrome occurs more often in females than males, in subjects who are slim more than those who are obese, and in Asians more than in Caucasians.

In terms of ocular perfusion, Flammer syndrome is often associated with reduced autoregulation of OBF, increased RVP, stiffer retinal vessels, reduced neurovascular coupling, optic disc haemorrhages, and a correlation between OBF and finger blood flow.

A potential treatment in Flammer syndrome are CCBs in low doses as they reduce the vasoconstrictive effect of ET-1, leading to vasodilation or relief from vasospasm. CCBs reduce RVP and improve the regulation of OBF. For more details,

please refer to recent major reviews [11–12].

Vasospastic syndrome (today called Flammer syndrome) has already been described as a risk factor for both retinal arterial and vein occlusions [12,14]. CLRAO is often combined with CRVO, and the disturbed venous outflow may be one of the causes of CLRAO [9–10]. Flammer syndrome is often associated with increased RVP [12], and the increase of RVP and CRVO may be due to a dysregulation of the retinal vein [15]. Here we described a case with all three aspects: CLRAO, very high RVP, and Flammer syndrome. We hypothesize that Flammer syndrome caused both a constriction of the cilioretinal artery and an increase of RVP due to a local constriction of the central retinal vein and thereby contributed to CLRAO. The fast improvement of all vascular parameters after a CCB therapy further supports this hypothesis.

Based on our clinical experience, vitamin D serum level is often low in patients with Flammer syndrome. This relationship needs to be studied in the future along with the effect of vitamin D supplementation on the course of CLRAO and other diseases related to Flammer syndrome.

Conclusion

The lack of classical risk factors for arterial occlusions and of identifiable sources of emboli and the presence of markedly increased RVP and disturbed regulation of retinal vessels in both eyes led us to the hypothesis that Flammer syndrome has predisposed this young patient to CLRAO, while vitamin D deficiency may have further increased the risk.

Conflict of Interest: None.

K. Konieczka, M. G. Todorova, T. N. Chackathayil, P. B. Henrich

Department of Ophthalmology, University of Basel, Basel, Switzerland (Chairman ad interim: Dr. N. Spirig)

References

1 Justice J jr., Lehmann RP. Cilioretinal arteries. A study based on review of stereo fundus photographs and fluorescein angiographic findings. Arch Ophthalmol 1976; 94: 1355–1358

- 2 Brown GC, Shields JA. Cilioretinal arteries and retinal arterial occlusion. Arch Ophthalmol 1979; 97: 84–92
- 3 Stoffelns BM. [Isolated cilioretinal artery occlusion – clinical findings and outcome in 31 cases]. Klin Monatsbl Augenheilkd 2012; 229: 338–342
- 4 Greven CM, Slusher MM, Weaver RG. Retinal arterial occlusions in young adults. Am J Ophthalmol 1995; 120: 776–783
- 5 Kannan B, Balaji V, Kummararaj S et al. Cilioretinal artery occlusion following intranasal cocaine insufflations. Indian J Ophthalmol 2011; 59: 388–389
- 6 McCannel CA. Choroidal infarction or cilioretinal artery occlusion in the setting of elevated intracranial pressure due to fulminant idiopathic intracranial hypertension? J Neuroophthalmol 2011; 31: 194–195
- 7 Chang L, Mruthyunjaya P, Rodriguez-Rosa RE et al. Postoperative cilioretinal artery occlusion in Sturge Weber-associated glaucoma. J AAPOS 2010; 14: 358–360
- 8 Zhang L, Sun Y, Johnson MW. Combined cilioretinal artery and central vein occlusions in juvenile glaucoma. Arch Ophthalmol 2011; 129: 1231–1234
- 9 Schatz H, Fong AC, McDonald HR et al. Cilioretinal artery occlusion in young adults with central retinal vein occlusion. Ophthalmology 1991; 98: 594–601
- 10 Hayreh SS, Fraterrigo L, Jonas J. Central retinal vein occlusion associated with cilioretinal artery occlusion. Retina 2008; 28: 581–594
- 11 Konieczka K, Ritch R, Traverso CE et al. Flammer syndrome. EPMA J 2014; 5: 11
- 12 Flammer J, Konieczka K, Flammer AJ. The primary vascular dysregulation syndrome: implications for eye diseases. EPMA J 2013; 4: 14
- 13 Flammer J, Konieczka K, Bruno RM et al. The eye and the heart. Eur Heart J 2013; 34: 1270–1278
- 14 Flammer J, Pache M, Resink T. Vasospasm, its role in the pathogenesis of diseases with particular reference to the eye. Prog Retin Eye Res 2001; 20: 319–349
- 15 Fraenkl SA, Mozaffarieh M, Flammer J. Retinal vein occlusions: The potential impact of a dysregulation of the retinal veins. EPMA J 2010; 1: 253–261

Bibliography

DOI <http://dx.doi.org/10.1055/s-0035-1545774>
Klin Monatsbl Augenheilkd 2015; 232: 576–578
© Georg Thieme Verlag KG Stuttgart · New York · ISSN 0023-2165

Correspondence

Katarzyna Konieczka, MD
University of Basel
Department of Ophthalmology
Mittlere Strasse 91
4031 Basel
Switzerland
Tel.: +41(0)6 1265 8803
Fax: +41(0)6 1265 8652
Katarzyna.Konieczka@usb.ch